

## CURRENT TOPIC

## Mitochondrial disorders and the kidney

Patrick Niaudet

Mitochondrial disorders are genetic defects of oxidative phosphorylation which can affect different organs or tissues.<sup>1 2</sup> These disorders have long been regarded as neuromuscular diseases only,<sup>3</sup> but it now appears that they can affect a number of other organs including the heart, liver, pancreas, haematopoietic system, and the kidneys.<sup>4</sup> Renal symptoms appear to be more common in children than in adults.

**The mitochondrial respiratory chain**

Oxidative phosphorylation occurs in the mitochondrial inner membrane and includes the oxidation of fuel molecules by oxygen and the concomitant energy transduction into ATP. During the oxidation process, reducing equivalents are transferred to oxygen through the enzymatic complexes of the mitochondrial respiratory chain: complexes I, III, and IV for NADH producing substrates, complexes II, III, and IV for succinate (fig 1).<sup>5</sup> This energy is used by complexes I, III, and IV to pump protons through the mitochondrial inner membrane, which creates a charge differential. The ATP synthase allows protons to flow back into the mitochondrion and uses the released energy for the phosphorylation of ADP to ATP.

**The mitochondrial genome**

The mitochondrial respiratory chain is a complex metabolic pathway. It is made up of about 100 polypeptides. Most of these are encoded in the nucleus and 13 are encoded in the mitochondria. Mitochondria contain their own DNA. In humans, each mitochondrion contains between two and 10 molecules of mitochondrial DNA (mtDNA), which is a 16.5 kb circular double stranded DNA with two distinct origins of replication. It encodes two ribosomal RNAs, 22 tRNAs, and 13 subunits of the polypeptide enzymes of the respiratory chain: seven subunits for complex I, one subunit for complex III, three subunits for complex IV, and two subunits for complex V.<sup>6</sup> The remainder of these complexes, as well as proteins involved in the replication, transcription, and translation of the mtDNA, are encoded by the nuclear DNA. The replication, transcription, and translation of mtDNA are independent of nuclear DNA.

**Mitotic segregation, heteroplasmy, and maternal inheritance**

During cell division, mitochondria are randomly transmitted into daughter cells. In most cases, mtDNA copies in the mitochondria are

identical, a condition named homoplasmy. In cases with mtDNA mutation, the mitochondrion contains a mixture of normal or wild-type (wt) DNA and mutant mtDNAs named heteroplasmy.<sup>7</sup> During mitotic cell division, mitochondria are randomly partitioned to daughter cells. When normal and mutant mtDNA are present in mother cells, some daughter cells may drift towards purely mutant mtDNA or purely normal DNA, while others remain heteroplasmic. Therefore the mtDNA genotype can shift during the cell replication. The phenotype is defined not only by the nature of the mutation but also by the amount of mutant mtDNA in a given tissue. The phenotype also depends on the extent to which the cell type relies on mitochondrial function, and a tissue with only 20% of mutated DNA may have a normal phenotype. The phenotype of a given tissue may also vary with time according to the proportion of mutated mtDNA.

Mitochondria are transmitted through the egg cytoplasm. As only the nuclear DNA from sperm is retained during fertilisation, the mitochondrial genome is maternally transmitted.<sup>8</sup> The mother transmits her mtDNA to all her progeny and her daughters transmit their mtDNA to the next generation. Males never transmit their mtDNA.

**Clinical symptoms**

Mitochondrial cytopathies result from a defect of oxidative phosphorylation, particularly a deficiency of one of the respiratory chain complexes. Mitochondria are present in all cells (except erythrocytes) and consequently a disorder of oxidative phosphorylation can theoretically give rise to a wide range of symptoms in any organ or tissue. From a clinical point of view, one should consider the diagnosis of mitochondrial disorder when dealing with an unexplained association of symptoms involving seemingly unrelated organs which share no common embryological origin or biological functions.<sup>9</sup>

The first symptoms are observed before 1 month of age in more than a third of cases and before the age of 2 years in 80% of cases. Myopathy is responsible for muscle weakness and exercise intolerance. Chronic progressive ophthalmoplegia with ptosis, limitation of eye movement, and diplopia may be isolated or associated with pigmentary retinopathy, ataxia, and heart block (Kearns-Sayre syndrome).<sup>10</sup> The central nervous system may be predominantly involved, with psychomotor retardation,

Néphrologie  
Pédiatrique,  
Fédération de  
Pédiatrie, and  
INSERM U 423,  
Hôpital Necker  
Enfants Malades,  
Paris, France

Correspondence to:  
Dr P Niaudet, Néphrologie  
Pédiatrique, Hôpital Necker  
Enfants Malades, 149 rue de  
Sèvres, 75743 Paris cedex  
15, France.

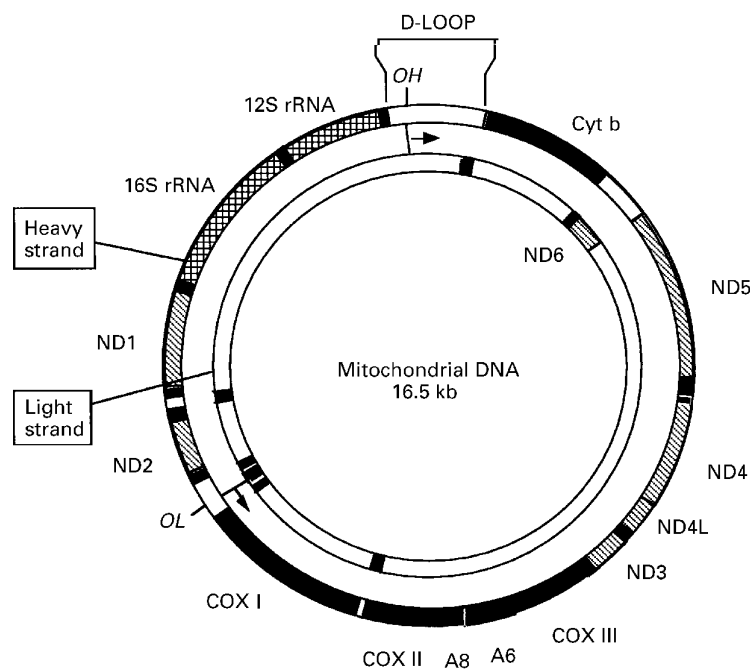


Figure 1 The mitochondrial respiratory chain.

seizures, stroke, sensorineural hearing loss, optic atrophy, ataxia, myoclonus, and dementia.<sup>11</sup> Several clinical entities have been described according to the clinical presentation (table 1).

Other organs may be affected. Endocrine gland involvement may cause diabetes mellitus, growth hormone deficiency, hypothyroidism, and hypoparathyroidism. Cardiac symptoms consist of hypertrophic cardiomyopathy and conduction defects. Gastrointestinal symptoms include vomiting and colonic pseudo-obstruction. Pearson's syndrome is characterised by the association of sideroblastic anaemia, thrombocytopenia, neutropenia, hepatocellular dysfunction, exocrine pancreatic dysfunction, and proximal tubulopathy.

Several reports have described alterations of the mitochondrial genome in patients with insulin dependent or insulin independent diabetes mellitus.<sup>12</sup> These patients may develop diabetic nephropathy. Patients with Kearns-Sayre syndrome often develop diabetes mellitus. A mutation of mtDNA has been described in several families with maternally transmitted

diabetes mellitus and deafness.<sup>13</sup> Such mutation of mtDNA, also described in patients with MELAS syndrome, may affect Langerhans cells and contribute to the disease. It can be estimated that 1–2% of patients with diabetes mellitus have a mitochondrial cytopathy.

### Renal symptoms

Renal disease has more often been reported in children than in adults. The commonest renal manifestation is a proximal tubulopathy, resulting in a form of the de Toni-Debré-Fanconi syndrome.<sup>14–19</sup> The reason for the predominance of this form of renal disease is that ATP is essential to drive the sodium-potassium-ATPase pump. This generates the electrical gradient across the proximal tubular epithelium and maintains a low concentration of sodium in the cell compared with the outside. This gradient drives all the activities of the proximal tubular cell. All the other absorptive functions—for sugar, phosphate, amino acids, and so on—are handled through cotransporters. The de Toni-Debré-Fanconi syndrome includes urinary losses of amino acids, glucose, proteins, phosphate, uric acid, calcium, bicarbonate, potassium, sodium, and water. The proximal tubulopathy is often moderate, and several investigators have reported isolated hyperaminoaciduria. Other patients may have acidosis, hypophosphataemic rickets, hypercalciuria, glycosuria, and tubular proteinuria. Renal biopsy shows non-specific abnormalities of the tubular epithelium with dilatation and obstruction by casts, dedifferentiation, or atrophy. Giant mitochondria are often observed. Extrarenal symptoms are always present, including myopathy, neurological symptoms, Pearson's syndrome, diabetes mellitus, or cardiac problems. Tubular symptoms have been described before the age of 2 years in the majority of patients, and more than 40% of them have died during the first year of life.

Glomerular disease with nephrotic syndrome has been described in a few patients with mitochondrial cytopathies.<sup>20</sup> Renal biopsy in these patients shows lesions of segmental and focal glomerular sclerosis which may progress, with impairment of glomerular filtration rate. The nephrotic syndrome does not respond to any form of treatment.

A tubulointerstitial nephropathy has been described.<sup>21 22</sup> The clinical presentation is

Table 1 Clinicopathological entities in mitochondrial disorders

Kearns-Sayre syndrome	Progressive external ophthalmoplegia, retinal pigmentary degeneration, cerebellar ataxia, heart block
MERRF (myoclonic epilepsy and ragged red fibres)	Encephalomyopathy with myoclonus, epilepsy, ataxia, myopathy, hearing loss, dementia
LHON (Leber hereditary optic neuropathy)	Blindness, cardiac arrhythmias
MELAS (mitochondrial encephalomyopathy, lactic acidosis and stroke-like episodes)	Headache, vomiting, lactic acidosis, myopathy with ragged red fibres, seizures, dementia, deafness
Leigh's disease	Subacute necrotising encephalomyopathy, ataxia, respiratory problems with weak cry, deafness, blindness
CPEO (chronic progressive external ophthalmoplegia) and mitochondrial myopathy	Ocular myopathy, retinal pigmentary degeneration, central nervous system dysfunction
Alpers' disease	Progressive infantile poliodystrophy, hepatic failure

characterised by polyuria secondary to a urinary concentrating defect and by a progression to terminal renal failure. Patients do not show proximal tubular defects. Histological lesions on renal biopsy consist of diffuse interstitial fibrosis with tubular atrophy and sclerotic glomeruli within the area of interstitial fibrosis. All the reported cases also had extrarenal symptoms.

### Laboratory studies

Since the respiratory chain transfers NADH to oxygen, a disorder of oxidative phosphorylation results in an altered oxidoreduction status in plasma. This feature is a result of functional impairment of the Krebs cycle owing to the excess of NADH and the lack of NAD, with a secondary rise in blood lactate and an increase in ketone body and lactate/pyruvate molar ratios. This is particularly true in the post-absorptive period, when more NAD is required for adequate metabolism of glycolytic substrates.<sup>23</sup> As a further result of the Krebs cycle impairment, ketone body synthesis increases after meals instead of decreasing, owing to the channelling of acetyl-CoA toward ketogenesis. Consequently, the screening for mitochondrial disorders includes the determination of lactate, pyruvate, ketone bodies, and their molar ratios in both fasted and fed individuals. However, a normal oxidoreduction status may occasionally be observed, particularly in patients with proximal tubulopathy. In these patients, impaired proximal tubular reabsorption may lower blood lactate and increase urinary organic acid excretion. For this reason, a normal plasma lactate concentration does not rule out a mitochondrial disorder in a patient with proximal tubulopathy. In these cases, the clue to the diagnosis lies in the presence of other unrelated symptoms.

The activity of the different enzymatic complexes of the respiratory chain is most often evaluated by polarographic and spectrophotometric studies. Polarographic studies consists of the measurement of oxygen consumption by isolated mitochondria or whole cells in the presence of various oxidative substrates (pyruvate, glutamate, succinate, palmitate, and so on). These studies can be performed on peripheral blood mononuclear cells, skin fibroblasts, or a muscle biopsy specimen. Enzyme activities are assessed by spectrophotometric studies on isolated mitochondria or on tissue homogenates. A renal biopsy can be done in cases of nephropathy but other tissues may be more accessible for such spectrophotometric studies, for example skeletal muscle, skin fibroblasts, or peripheral blood mononuclear cells.<sup>24</sup>

Histopathological studies may also contribute. The presence on muscle biopsy of ragged red fibres with irregularly shaped aggregates of abnormal mitochondria and lipid droplets between the fibrils is characteristic of mitochondrial myopathy, but their absence does not rule out the diagnosis. The ragged red fibres may be seen using the modified Gomori trichrome technique. Similarly, the presence of

cytochrome *c* oxidase negative fibres is highly suggestive of mitochondrial disorder.

Large rearrangements of mtDNA are detected by Southern blot analysis, and mtDNA point mutations by polymerase chain reaction (PCR) amplification and the sequence of total genomic DNA derived from various tissues. These studies cannot be performed routinely, and negative results do not rule out an mtDNA mutation.<sup>18</sup>

### Treatment

There is at present no satisfactory treatment for mitochondrial cytopathies.<sup>25</sup> Patients should avoid sodium valproate, barbiturates, tetracyclines, and chloramphenicol as they may interfere with the respiratory chain. Lactic acidosis may be exacerbated by exercise or intercurrent infections. In such cases, slow infusion of sodium bicarbonate should be prescribed. Other symptomatic prescriptions include pancreatic extract in case of exocrine pancreatic dysfunction or transfusions in case of anaemia.

Cases with complex III deficiency may be improved with menadione (vitamin K-3, 40–160 mg/day) or ubidecarone (coenzyme Q10, 80–300 mg/day). Similarly, patients with complex I deficiency may be treated with riboflavin (100 mg/day) and ubidecarone. Carnitine is given to patients with secondary carnitine deficiency. Ascorbic acid has been given in order to prevent oxygen radical damage. Steroid treatment may improve headaches and stroke-like episodes.

Dietary recommendations include a low carbohydrate/high lipid diet in patients with cytochrome *c* oxidase deficiency.

### Conclusions

Consideration should be given to genetic defects of mitochondrial energy supply in elucidating the origin of unexplained renal disorders, especially when dealing with an association of symptoms involving seemingly unrelated organs which share no common embryological origin and no common biological functions.

- 1 Johns DR. Mitochondrial DNA and disease. *N Engl J Med* 1995;333:638–44.
- 2 Luft R. The development of mitochondrial medicine. *Proc Natl Acad Sci USA* 1994;91:8731–8.
- 3 Luft R, Ikkos D, Palmieri G, Ernster L, Afzelius B. A case of severe hypermetabolism of nonthyroid origin with a defect in the maintenance of mitochondrial respiratory control; a correlated clinical, biochemical and morphological study. *J Clin Invest* 1962;41:1776–804.
- 4 Sengers RCA, Stadhouders AM, Trijbels JMF. Mitochondrial myopathies: clinical, morphological and biochemical aspects. *Eur J Pediatr* 1984;141:192–207.
- 5 Hatefi Y. The mitochondrial electron transport and oxidative phosphorylation system. *Annu Rev Biochem* 1985;54:1015–69.
- 6 Clayton DA. Structure and function of the mitochondrial genome. *J Inherit Metab Dis* 1992;15:439–47.
- 7 Wallace DC. Maternal genes: mitochondrial diseases. *Birth Defects* 1987;23:137–90.
- 8 Giles RE, Blanc H, Cann HM, Wallace DC. Maternal inheritance of human mitochondrial DNA. *Proc Natl Acad Sci USA* 1980;77:6715–19.
- 9 Munnich A, Rustin P, Rötig A, et al. Clinical aspects of mitochondrial disorders. *J Inherit Metab Dis* 1992;15:448–55.
- 10 Petty RKH, Harding AE, Morgan-Hughes JA. The clinical features of mitochondrial myopathy. *Brain* 1986;109:915–38.
- 11 DiMauro S, Bonilla E, Lombes A, Shanske S, Minetti C, Moraes CT. Mitochondrial encephalomyopathies. *Neurol Clin* 1990;8:483–506.

- 12 Reardon W, Ross RJM, Sweeney MG, *et al.* Diabetes mellitus associated with a pathogenic point mutation in mitochondrial DNA. *Lancet* 1992;340:1376-9.
- 13 Van den Ouweland PAA, Lemkes HHPJ, Ruitenbeeck W, *et al.* Mutation in mitochondrial tRNA<sup>Leu</sup>(UUR) gene in a large pedigree with maternally transmitted type II diabetes mellitus and deafness. *Nat Genet* 1992;1:368-71.
- 14 Majander A, Suomalainen A, Vetterrannta K, *et al.* Congenital hypoplastic anemia, diabetes, and severe renal tubular dysfunction associated with a mitochondrial DNA deletion. *Pediatr Res* 1991;30:327-30.
- 15 Morris AAM, Taylor BW, Birch-Machin MA, *et al.* Neonatal Fanconi syndrome due to deficiency of complex III of the respiratory chain. *Pediatr Nephrol* 1995;9:407-11.
- 16 Niaudet P, Heidet L, Munnich A, *et al.* Deletion of the mitochondrial DNA in a case of de Toni-Debré-Fanconi syndrome and Pearson syndrome. *Pediatr Nephrol* 1994;8:164-8.
- 17 Ogier H, Lombes A, Sholte HR, *et al.* De Toni-Fanconi-Debré syndrome with Leigh syndrome revealing severe muscle cytochrome c oxidase deficiency. *J Pediatr* 1988;112:734-9.
- 18 Rötig A, Bessis JL, Romero N, *et al.* Maternally inherited duplication of the mitochondrial genome in a syndrome of proximal tubulopathy, diabetes mellitus and cerebellar ataxia. *Am J Hum Genet* 1992;50:364-70.
- 19 Sperl W, Ruitenbeeck W, Trijbels JMF, Sengers RCA, Stadhouders AM, Guggenbichler JP. Mitochondrial myopathy with lactic acidemia, Fanconi-de Toni-Debré syndrome and a disturbed succinate-cytochrome c oxidoreductase activity. *Eur J Pediatr* 1988;147:418-21.
- 20 Niaudet P, Rötig A. The kidney in mitochondrial cytopathies. *Kidney Int* 1997;51:1000-7.
- 21 Donaldson MDC, Warner AA, Trompeter RS, Haycock GB, Chantler C. Familial juvenile nephronophthisis, Jeune's syndrome, and associated disorders. *Arch Dis Child* 1985;60:426-34.
- 22 Rötig A, Goutières F, Niaudet P, *et al.* Deletion of mitochondrial DNA in patient with chronic tubulointerstitial nephritis. *J Pediatr* 1995;126:597-601.
- 23 Chrétien D, Bourgeron T, Rötig A, Munnich A, Rustin P. The measurement of the rotenone sensitive NADH cytochrome C reductase activity in mitochondria isolated from minute amount of human skeletal muscle. *Biochem Biophys Res Commun* 1990;173:26-33.
- 24 Rustin P, Chrétien D, Gérard B, *et al.* Biochemical, molecular investigations in respiratory chain deficiencies. *Clin Chim Acta* 1993;228:35-51.
- 25 Przyrembel H. Therapy of mitochondrial disorders. *J Inher Metab Dis* 1987;10:129-46.



## Mitochondrial disorders and the kidney

Patrick Niaudet

*Arch Dis Child* 1998 78: 387-390  
doi: 10.1136/adc.78.4.387

---

Updated information and services can be found at:  
<http://adc.bmj.com/content/78/4/387>

- 
- References** *These include:* This article cites 22 articles, 4 of which you can access for free at:  
<http://adc.bmj.com/content/78/4/387#BIBL>
- Email alerting service** Receive free email alerts when new articles cite this article. Sign up in the box at the top right corner of the online article.

---

### Topic Collections

Articles on similar topics can be found in the following collections

[Metabolic disorders](#) (739)  
[Muscle disease](#) (60)  
[Neuromuscular disease](#) (158)  
[Rheumatology](#) (502)  
[Pancreas and biliary tract](#) (262)  
[Drugs: CNS \(not psychiatric\)](#) (473)

---

### Notes

---

To request permissions go to:  
<http://group.bmj.com/group/rights-licensing/permissions>

To order reprints go to:  
<http://journals.bmj.com/cgi/reprintform>

To subscribe to BMJ go to:  
<http://group.bmj.com/subscribe/>